

PRESSURE SORE DATA COLLECTION

SKIN ASSESSMENT TOOL

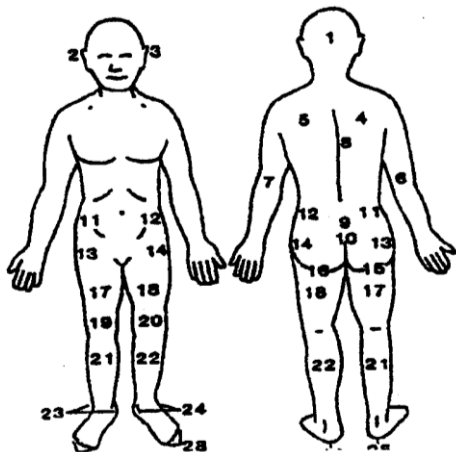
Name: _____

ID Number: _____

DATE OF OBSERVATION: _____ Skin Temperature: _____ Tissue consistency: _____ Sensation: _____
 (MM/DD/YEAR)

ASSESSMENT SITE*	SKIN CONDITION		
	Size	Depth	Stage
1) Back of head			
2) Right ear			
3) Left ear			
4) Right scapula			
5) Left scapula			
6) Right elbow			
7) Left elbow			
8) Vertebrae (upper-mid)			
9) Sacrum			
10) Coccyx			
11) Right iliac crest			
12) Left iliac crest			
13) Right trochanter (hip)			
14) Left trochanter (hip)			
15) Right ischial tuberosity			
16) Left ischial tuberosity			
17) Right thigh			
18) Left thigh			
19) Right knee			
20) Left knee			
21) Right lower leg			
22) Left lower leg			
23) Right ankle (inner/outer)			
24) Left ankle (inner/outer)			
25) Right heel			
26) Left heel			
27) Right toe(s)			
28) Left toe(s)			
29) Other (specify)			

* Assess and record each site each observation time. Mark site(s) on figure below.



Stage 1	Intact skin with non-blanchable redness of a localized area usually over a bony prominence. Darkly pigmented skin may not have visible blanching; its color may differ from the surrounding area.
Stage 2	Partial thickness loss of dermis presenting as a shallow open ulcer with a red pink wound bed, without slough. May also present as an intact or open/ruptured serum-filled blister.
Stage 3	Full thickness tissue loss. Subcutaneous fat may be visible but bone, tendon or muscle are not exposed. Slough may be present but does not obscure the depth of tissue loss. May include undermining and tunneling.
Stage 4	Full thickness tissue loss with exposed bone, tendon or muscle. Slough or eschar may be present on some parts of the wound bed. Often include undermining and tunneling.
Unstageable: See description on back	

Outreach Services of Indiana, rev. June, 2008

Stage I:

Intact skin with non-blanchable redness of a localized area usually over a bony prominence. Darkly pigmented skin may not have visible blanching; its color may differ from the surrounding area.

Further description:

The area may be painful, firm, soft, warmer or cooler as compared to adjacent tissue. Stage I may be difficult to detect in individuals with dark skin tones. May indicate "at risk" persons (a heralding sign of risk)

Stage II:

Partial thickness loss of dermis presenting as a shallow open ulcer with a red pink wound bed, without slough. May also present as an intact or open/ruptured serum-filled blister.

Further description:

Presents as a shiny or dry shallow ulcer without slough or bruising.* This stage should not be used to describe skin tears, tape burns, perineal dermatitis, maceration or excoriation.

***Bruising indicates suspected deep tissue injury**

Stage III:

Full thickness tissue loss. Subcutaneous fat may be visible but bone, tendon or muscle are not exposed. Slough may be present but does not obscure the depth of tissue loss. May include undermining and tunneling.

Further description:

The depth of a stage III pressure ulcer varies by anatomical location. The bridge of the nose, ear, occiput and malleolus do not have subcutaneous tissue and stage III ulcers can be shallow. In contrast, areas of significant adiposity can develop extremely deep stage III pressure ulcers. Bone/tendon is not visible or directly palpable.

Stage IV:

Full thickness tissue loss with exposed bone, tendon or muscle. Slough or eschar may be present on some parts of the wound bed. Often include undermining and tunneling.

Further description:

The depth of a stage IV pressure ulcer varies by anatomical location. The bridge of the nose, ear, occiput and malleolus do not have subcutaneous tissue and these ulcers can be shallow. Stage IV ulcers can extend into muscle and/or supporting structures (e.g., fascia, tendon or joint capsule) making osteomyelitis possible. Exposed bone/tendon is visible or directly palpable.

Unstageable:

Full thickness tissue loss in which the base of the ulcer is covered by slough (yellow, tan, gray, green or brown) and/or eschar (tan, brown or black) in the wound bed.

Further description:

Until enough slough and/or eschar is removed to expose the base of the wound, the true depth, and therefore stage, cannot be determined. Stable (dry, adherent, intact without erythema or fluctuance) eschar on the heels serves as "the body's natural (biological) cover" and should not be removed.